

ABNORMALITIES IN LATERAL THORACIC RADIOGRAPHS OF DOMESTIC DOGS WITH COUGHING

Arville Mar Gregorio A. Pajas, Relson B. Lozano, Rey B. Oronan,
Marianne Leila S. Flores and Karlo Romano B. Gicana

ABSTRACT

Lateral thoracic radiographs of dogs presented with coughing were assessed to determine abnormalities in selected thoracic structures. Thirty radiographic images were used to describe tracheal diameter and thoracic inlet ratio (TD:TI), pulmonary patterns present, cardiac silhouette abnormalities and vertebral heart size (VHS). Data collected were classified and grouped based on the age of the animal (growing, adult, senior) and the cephalic index. The TD:TI ratio was normal in all radiographs regardless of cephalic index. Majority of pulmonary patterns observed in dogs with cough were mixed patterns consisting of alveolar and bronchial forms. Loss of cranial waist and generalized cardiac enlargement were commonly seen in adult and senior dogs. Also, above normal VHS was observed in these animals, suggesting cardiac enlargement. The various radiographic abnormalities found in coughing dogs suggest that a more thorough clinical examination of patients must be done to rule out primary cardiac disease and secondary respiratory problems.

Keywords: cardiorespiratory, coughing, dog, radiography, tracheal diameter: thoracic inlet ratio, vertebral heart size

INTRODUCTION

The cough reflex in most mammalian species plays a vital role in protecting the air passageway from potential harm when the specialized epithelial barrier and immune system are overwhelmed by noxious exogenous and endogenous stimuli (King, 2010). However, when it

Department of Veterinary Clinical Sciences, College of Veterinary Medicine, University of the Philippines Los Baños, College, Laguna, Philippines (email: arville_pajas@yahoo.com)

becomes excessive and inapt in an animal, this protective reflex presents a diagnostic and therapeutic dilemma in the practicing veterinarian handling the case (Atkins, 2005). In domestic dogs, coughing is an indication of underlying disorder (Rozanski, 2005) particularly those affecting the respiratory system (Morais, 2009) and the cardiovascular system (King, 2010). Coughing observed in dogs at night and during awakening is associated with chronic bronchitis, chronic interstitial disease and left sided cardiac failure (Corcoran and Darke, 1999). The alterations on the organs related to the cardiovascular and respiratory systems can be visually observed in the thoracic radiographs in a dog with cough, hence this study.

Thoracic radiographs provide valuable information relative to cardiac size, gross chamber abnormalities, alteration in the size and appearance of great vessels, distortion of the pulmonary and cardiovascular vessel size, abnormalities of the chest wall, pleural space, and the lung itself particularly the bronchi, interstitial spaces and alveolar tissues (Fox, 2007). These can provide useful information to differentiate primary cardiac disease from respiratory problems in coughing dogs (Spier, 2011).

Coughing is elicited in various cardiopulmonary diseases. Foreign body obstruction and upper airway tumors are less commonly associated with coughing compared to tracheal collapse (Gaschen, 2010). Tracheal diameter and thoracic inlet ratio is used to objectively assess tracheal collapse (Gaschen, 2010).

Various cardiopulmonary diseases associated with coughing can cause changes in the lung opacities. These changes can be best described using the pattern-based approach. In this method, pulmonary changes on the opacities of the lung are classified based on their structure(s) (Berry *et al.*, 2007).

Cardiac silhouette changes in coughing dogs would include the enlargement of either side of the heart. Left or right-sided cardiomegaly or generalized cardiomegaly can lead to increased vertebral heart size (VHS) in dogs with coughing. In a study done by Guglielmini *et al.* (2009), VHS was reported to be abnormal in dogs suffering from cardiac diseases and in mixed causes of coughing.

At present, data on the most common radiographic findings on dogs presented with coughing in small animal practice in the Philippines is not yet available. This study will help our understanding of coughing and its radiographic features for better therapeutic management and prognosis.

MATERIALS AND METHODS

Medical records of canine patients with chief complaint of coughing presented at the University of the Philippines Veterinary Teaching Hospital Diliman, Quezon City from January 2005 through October 2011 were

retrieved. From the medical records, the radiograph numbers of individual patients were extracted. Thoracic radiographs of individual patients were searched and retrieved from the radiograph archives of the hospital. These radiographs were evaluated based on the quality, positioning and projections. Only radiographs with distinct detail and contrast were utilized in this study. In addition, only left and right latero-lateral radiographic views were used for the current study.

Information about the name of the patient, sex, breed, date of birth, age upon presentation and body weight were noted. The animals in this study were grouped based on the age and cephalic index. Age groups are classified as growing (<1 ½ years), adult (1 ½ to 7 years) or senior (> 7 years). On the other hand, cephalic index can either be described as brachycephalic or non-brachycephalic.

Evaluation of the thoracic radiographs of individual dogs was performed over a negathoscope. The latero-lateral thoracic radiographs were categorized based from the descriptions of Rudolf *et al.* (2008) (entry-exit points of the X-ray beam on the dog's body and the respiratory phase when the radiograph was taken). Each radiograph was read systematically in a cranio-caudal manner.

The distance of the thoracic inlet and luminal diameter of the trachea in the thoracic region was measured using a caliper according to the method described by Coyne and Finland (1992). Measurements from these thoracic structures were expressed to the nearest millimeter. The ratio of the thoracic tracheal lumen diameter (TD) and thoracic inlet distance (TI) of individual dogs was calculated using the formula:

$$\text{Ratio}_{\text{TD \& TI}} = \frac{\text{Thoracic tracheal lumen diameter (TD)}}{\text{Thoracic inlet distance (TI)}}$$

The pulmonary patterns present on the lung fields were then described and categorized as inspiratory latero-lateral thoracic radiograph as alveolar, interstitial, bronchial and vascular pattern as reported by Kealy and McAllister (2000). The cardiac silhouette was characterized either as loss of cranial waist, presence of dilated pulmonary artery, loss of caudal waist or generalized cardiac enlargement. The vertebral heart size (VHS) was measured based on the method described by Buchanan and Bucheler (1995). Measurements of the long axis and short axis of the cardiac silhouette were done using a caliper. The value of the VHS was calculated using the formula and expressed in vertebra (v):

$$\text{Vertebral Heart Size} = \text{Long Axis (v)} + \text{Short Axis (v)}$$

Radiographic findings observed were analyzed based on age and cephalic index using descriptive statistics. The mean±SD were calculated for the ratio of the tracheal diameter and thoracic inlet distance, and the vertebral heart size. The pulmonary patterns and cardiac silhouette abnormalities were reported in frequency.

RESULTS AND DISCUSSION

In this study, 30 cases of coughing dogs were evaluated based on the latero-lateral thoracic radiographic features of the cardiac silhouette and lungs. The study included the measurement of TD:TI, description of common pulmonary patterns, evaluation of cardiac silhouette and measurement of vertebral heart size. There were 16 inspiratory and 14 expiratory latero-lateral radiographs used in this study.

The mean TD: TI of coughing dogs based on cephalic index is reported in Table 1. This measurement was employed to assess if tracheal narrowing occurred among dogs presented with coughing. This tracheal narrowing is commonly seen in congenital abnormalities like tracheal hypoplasia (Owens and Biery, 1999). The results show that the relative tracheal diameter of all the dogs in the study are normal, based on the report of Harvey and Fink (1982). These suggest that coughing observed in these dogs may be due to either existing cardiovascular or respiratory diseases that do not involve alteration of the tracheal lumen. Furthermore, these imply that the narrowing of the tracheal lumen does not always cause coughing among dogs under study.

Table 1. Mean± SD of TD/ TI of dogs with cough presented at U.P. VTH Diliman, Quezon City from 2005 to 2011 arranged according to head conformation.

Breed	N	Mean±SD
Brachycephalic ¹	8	0.15 ± 0.03
Non-brachycephalic ²	22	0.16 ± 0.04
Total	30	

¹Brachycephalic breed: Shih Tzu

²Non-brachycephalic breeds: Japanese Spitz, Mixed, Labrador retriever, Maltese, Pomeranian, Toy Poodle

The common pulmonary patterns seen in coughing dogs are reported in Table 2. It showed that majority of the pulmonary patterns seen area mixture of at least two patterns. The presence of both alveolar (Figure 1) and bronchial (Figure 2) patterns is the most common findings in adult and senior dogs. Bronchial pattern is described as having the characteristic circular opacities with lucent centers (doughnut shaped) in the lung field (Mantis *et al.*, 2008). On the other hand, alveolar pattern has radiologic characteristics of poorly defined, increased densities with fluffy, indistinct margin that tend to coalesce (Fox, 2001). According to Dennis (2008), radiographic identification of 1 or more lung pattern is due to the close anatomical relationship between different tissues in the lungs and the pathophysiology of diseases. Senior dogs with cough commonly develop various pulmonary disorders. During this stage of life, the dogs are more susceptible to various diseases such as cardiovascular, respiratory and neoplastic diseases as a result of aging.

Table 2. Frequency of pulmonary patterns observed in dogs with inspiratory lateral thoracic radiograph arranged between age groups (N=16).

Age Group ¹	Pulmonary Pattern ²						Total
	A	B	AB	ABI	ABV	ABIV	
Growing	1	-	-	-	-	-	1
Adult	-	-	3	-	1	-	4
Senior	-	1	5	2	1	2	11
Total	1	1	5	2	1	2	16

¹Age Groups: Growing (< 1 ½ yr.), Adult (> 1 ½ yr. to 7 yr.), Senior (> 7 yr.)

²Pulmonary Pattern:

A= Alveolar; B = Bronchial; AB = Alveolar & Bronchial; ABI = Alveolar, Bronchial & Interstitial; ABV = Alveolar, Bronchial & Vascular; ABIV =Alveolar, Bronchial, Interstitial & Vascular

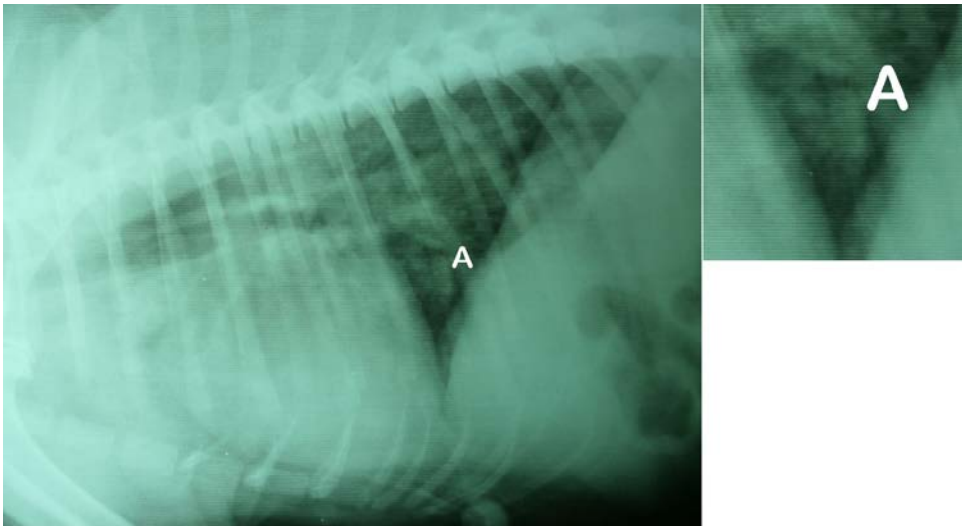


Figure 1. Right inspiratory lateral thoracic radiograph of a 6 year old mixed breed, intact male dog (BCS 5/9) showing alveolar patterns (A). The alveolar pattern is described as having cottony radiopaque appearance in the caudodorsal aspect of the lung field.

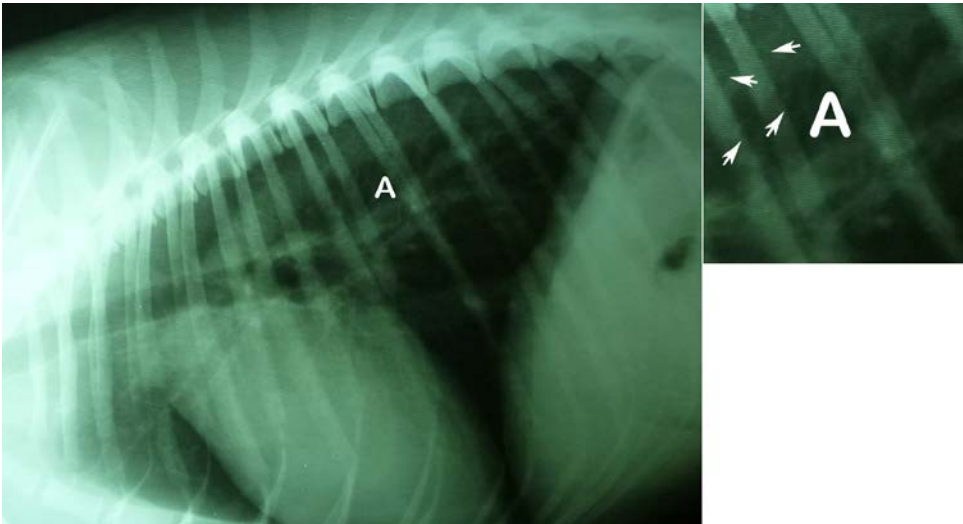


Figure 2. Right inspiratory lateral thoracic radiograph of a 1 year old Shih Tzu, intact female dog (BCS 4/9) showing bronchial patterns (A, white arrow heads). Bronchial pattern is described as having increased circular opacity with lucent center (doughnut shaped) in the perihilar region of the lungs.

Majority of cardiac silhouette abnormalities (Table 3) observed in dogs with cough were loss of cranial waist of cardiac silhouette (12/30) followed by loss of both cranial and caudal waists (as seen in Figure 3) of cardiac silhouette (11/30). Loss of cranial waist is indicative of right ventricular enlargement (Burk and Feeney, 2003). This enlargement may either be due to dilation of the ventricular diameter or hypertrophy of ventricular wall. On the other hand, radiographic evidence of loss of both cranial and caudal waists of the cardiac silhouette is indicative of generalized enlargement of the heart (Bahr, 2007). Generalized cardiomegaly is a condition wherein several chambers may be enlarged to the degree that no one chamber enlargement stands out (Bahr, 2007). This particular condition may be seen in dilated cardiomyopathies or other valvular diseases (Bahr, 2007).

Loss of caudal waist (0/12) was not observed in this study. This could be due to the greater sensitivity of thoracic radiographs in detecting right ventricular hypertrophy compared to left ventricular hypertrophy (Bahr, 2007). The obvious change in the shape and contour of the right ventricle observed during hypertrophy was attributed to the thinner wall of the right ventricle (Bahr, 2007).

Vascular pattern include hypervascularization due to increase in size and number of blood vessels that extends to the lung field (Kealy and McAllister, 2000). Dilation of the pulmonary arteries (Figure 3) (5/30) are seen in some dogs. They are either in combination with loss of

Table 3. Frequency of cardiac silhouette abnormalities observed in the inspiratory and expiratory lateral thoracic radiographs of selected dogs with chief complaint of coughing presented at U.P. VTH Diliman from 2005 to 2011 among age groups.

Age groups ¹	Cardiac silhouette abnormalities ²							Total
	Cr	Cd	Cr & Cd	Cr. w/ DPA	Cd. w/ DPA	Cr & Cd w/ DPA	NSC	
Growing	2	-	1	-	-	-	1	4
Adult	5	-	4	2	-	1	1	13
Senior	5	-	6	-	-	2	-	13
Total	12	-	11	2	-	3	2	30

¹Age Groups: Growing (< 1 ½ yr.), Adult (> 1 ½ yr. to 7 yr), Senior (> 7 yr.)

²Cr= Loss of cranial waist; Cd= Loss of caudal waist; Cr & Cd = Loss of both cranial & caudal waist; Cr w/ D.P.A. = Loss of cranial waist with dilated pulmonary artery; Cd w/ D. P. A. = Loss of caudal waist with dilated pulmonary artery; Cr and Cd w/ D.P.A. = loss of both cranial and caudal waist with dilated pulmonary artery; NSC= No significant change on cardiac silhouette

cranial waist (2/30) or loss of both cranial and caudal waists (3/30). Such findings are commonly observed in specific cardiovascular diseases like left to right shunt, patent ductus arteriosus or dirofilariasis (Bahr, 2007).

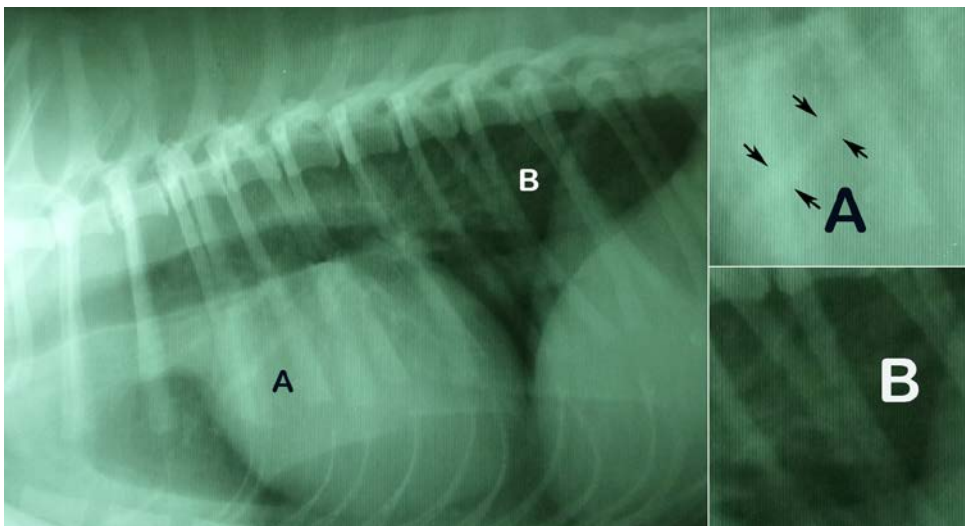


Figure 3. Left inspiratory lateral thoracic radiograph of a 3 year old Shih Tzu intact male dog (BCS 5/9) with increased cranial and caudal cardiac waists suggesting generalized cardiomegaly with respiratory disease complications. Vascular patterns (A), showing a band of soft tissue opacification, parallels the main course of cranioventral lobar airways and caudo-dorsal lung lobe region. Interstitial patterns with a mild soft tissue opacity (B) are also seen at the caudodorsal aspect of the lungs.

Among age groups, most of the cardiac silhouette abnormalities were commonly observed in senior and adult groups. Loss of cranial waist was commonly seen in adults (5/30) and seniors (5/30). On the other hand, the loss of both cranial and caudal waists were seen in adults (4/30) and senior (6/30). These observations may be related to an ongoing cardiovascular changes associated either with diseases or age. As cited by Guglielmini (2003), age related changes of the functional reserve and adaptability of cardiovascular system in geriatric dog include decreased blood flow and velocity, decreased arterial compliance and decreased distensibility. This can increase ventricular systolic and diastolic stiffness that can prolong the duration of myocardial contractility and subsequently alter functional reserve capacity (Guglielmini, 2003; Shearer, 2010).

The vertebral heart scale in coughing dogs were measured and reported in Table 4. Results show that adult and senior dogs have greater than the standard VHS range of $9.7v \pm 0.5v$ reported by Buchanan and Bucheler (1995). This data suggest that these dogs have cardiac enlargement. These cardiac enlargements may be related to pathological changes seen in cardiovascular diseases.

Table 4. Mean \pm SD and range of VHS measured in the inspiratory and expiratory lateral thoracic radiographs of selected dogs with chief complaint of coughing presented at U.P. VTH Diliman from 2005 to 2011.

Age Groups ¹	Inspiratory		Expiratory	
	N =16	Mean \pm SD	N =14	Mean \pm SD
Growing	1	8.8v \pm 0.0	3	8.3v \pm 1.6v
Adult	6	10.4 v \pm 0.6v	6	10.1v \pm 0.7v
Senior	9	10.8v \pm 1.2v	5	10.4v \pm 0.9v

¹Age Groups: Growing (< 1 ½ yr.), Adult (> 1 ½ yr. to 7 yr.), Senior (> 7 yr.)

The most common pulmonary pattern among different cardiac silhouette abnormalities during inspiratory phase observed is a combination of alveolar and bronchial patterns (7/16; Table 5). This is usually seen in loss of cranial waist (6/16) and loss of both cranial and caudal waists (1/16). These data suggest the various radiographic abnormalities that may be associated with coughing. The normal TD: TI ratio implied that tracheal narrowing is not usually seen in coughing dogs under study. Furthermore, the authors suggest that thoracic radiography be utilized as a routine test in dogs presented with coughing signs. The presence of pulmonary patterns suggests that an ongoing respiratory condition should be addressed. The cardiac enlargement should be carefully evaluated either as a primary cardiac disease or a secondary

respiratory problem thus, requiring a more thorough clinical examination either with an aid of electrocardiography and/or echocardiography.

Table 5. Frequency of pulmonary patterns relative to the cardiac silhouette abnormalities observed in the inspiratory lateral thoracic radiographs of dogs with cough presented at U.P. VTH Diliman, Quezon City from 2005 to 2011.

Cardiac Silhouette Abnormalities ¹	Pulmonary Pattern ²						Total
	A	B	AB	ABI	ABV	ABIV	
Cr	1	1	6	-	-	-	8
Cd	-	-	-	-	-	-	0
Cr & Cd	-	-	1	2	-	-	3
Cr w/DPA	-	-	-	-	1	1	2
Cd w/ DPA	-	-	-	-	-	-	0
Cr & Cd w/ DPA	-	-	-	-	2	1	3
NSC	-	-	-	-	-	-	0
Total	1	1	7	2	3	2	16

¹Cardiac silhouette abnormalities:

Cr= Loss of cranial waist; Cd= Loss of caudal waist; Cr & Cd = Loss of both cranial & caudal waist; Cr w/ D.P.A. = Loss of cranial waist with dilated pulmonary artery; Cd w/ D. P. A. = Loss of caudal waist with dilated pulmonary artery; Cr and Cd w/ D.P.A. = loss of both cranial and caudal waist with dilated pulmonary artery; NSC= No significant change on cardiac silhouette

²Pulmonary Patterns:

A= Alveolar; B = Bronchial; AB = Alveolar & Bronchial; ABI = Alveolar, Bronchial & Interstitial; ABV = Alveolar, Bronchial & Vascular; ABIV =Alveolar, Bronchial, Interstitial & Vascular

This study is the first known attempt to characterize and describe thoracic radiographs of patients presented with coughing. Based on the results, the recommended radiograph views for suspected cases of respiratory disease are right latero-lateral along with ventrodorsal views whereas right latero-lateral and dorsoventral views for suspected cases of cardiovascular disease. This can provide future reference in studies concerning cardiorespiratory medicine.

REFERENCES

- Atkins CE. 1994. Evaluation of cough in dogs with mitral valve insufficiency. *Compend Cont Edu Pract Vet* 16: 1547-1552.
- Atkins CE. 2009. Differentiation of Cardiac from Respiratory Disease in Dogs. In *Proceedings of TLAVC* Oct. 16-19, 2009, Lima, Peru, pp. 174-179.
- Bahr RJ. 2007. Heart and Pulmonary Vessels. In Thrall D (ed.). *Textbook of Veterinary Diagnostic Radiology*. 5thed. Missouri: Saunders Elsevier. pp. 568-590.

- Berry CR, Graham JP and Thrall DE. 2007. Interpretation Paradigms for the Small Animal Thorax. In Thrall D (ed.). *Textbook of Veterinary Diagnostic Radiology*. 5th ed. St. Louis, Missouri: Saunders Elsevier. pp. 462-485.
- Buchanan JW and Bucheler J. 1995. Vertebral scale system to measure canine heart size in radiographs. *J Am Vet Med A* 206: 194-199.
- Burk RL and Feeney DA. 2003. *Small Animal Radiology and Ultrasonography: A diagnostic atlas and text*. 3rd ed. Missouri, USA: WB Saunders Co. pp. 25-248.
- Corcoran BM. 2008. Common features of cardiac and respiratory disease: A diagnostic conundrum. In *Proceedings of the 33rd WSAVA Congress*, Dublin, Ireland, July 1-4, pp. 128-130.
- Corcoran BM and Darke BGG. 1999. The Respiratory System. In Chandler EA, Thompson DJ, Sutton JB and Price CJ (eds). *Canine Medicine and Therapeutics*. 3rd ed. Great Britain: Blackwell Scientific Publication. p. 42.
- Coyne BE and Fingland. 1992. Hypoplasia of the trachea in dogs: 103 cases (1974-1990). *J Am Vet Med A* 201: 768-771.
- Cunningham JG and Clein BG. 2007. *Textbook of Veterinary Physiology*. 4th ed. China: Saunders Elsevier. p. 613.
- Dennis R. 2008. Radiological assessment of lung disease in small animals: alveolar, interstitial and mixed lung pattern. *In Practice* 30: 262-270.
- Ettinger SJ. 1991. Ordering diagnostic tests in Cardiovascular disease. *Vet Clin N Am: Small* 21: 1081-1102.
- Ettinger SJ. 2000. Coughing. In Ettinger SJ and Feldman EC (eds). *Textbook of Veterinary Internal Medicine*. 5th ed. USA: WB Saunders Company. p. 163.
- Fox PR. 2001. Coughing and Dyspnea: Clinical Thoracic Radiography. <http://www.ivis.org>. Accessed 9 December 2011.
- Fox PR. 2007. Approach to the coughing and dyspneic dog. In *Proceedings of the WSAVA, Sydney, Australia, August 20-24*, pp. 1-5. <http://www.ivis.org/proceedings/wsava/2005/142.pdf>. Accessed 11 April 2013.
- Gaschen L. 2010. Airway Obstruction on Thoracic Radiographs. In *Proceedings of the 35th WSAVA Congress 2010, Geneva, Switzerland*. <http://www.ivis.org/proceedings/wsava/2010/c45.pdf>. Accessed 11 April 2013.
- Guglielmini C. 2003. Cardiovascular Diseases in the Ageing Dogs: Diagnostic and Therapeutic Problems. *Vet Res Commun* (Supplement) 27: 555.
- Guglielmini C, Diana A, Pietra M, Di Tomasso M, and Cipone M. 2009. Use of Vertebral Heart Score in Coughing Dogs with Chronic Degenerative Mitral Valve Disease. *J Vet Med Sci* 71: 9-13.
- Harvey CE and Fink EA. 1982. Tracheal diameter: Analysis of radiographic measurements in brachycephalic and nonbrachycephalic dogs. *J Am Anim Hosp Assoc* 18: 570-576.

-
- Kealy JK and McAllister H. 2000. *Diagnostic Radiology and Ultrasound of the Dog and Cat*. 3rd ed. USA: WB. Saunders Company. pp. 200-235.
- King LG. 1999. Chronic Cough. In Dunn JK (ed). *Textbook of Small Animal Medicine*. London: WB Saunders Company. pp. 93-94.
- King LG. 2010. Medical Management of the Coughing Dog: Heart Failure versus Lung Disease. *International Congress of the Italian Association of Companion Animal Veterinarian*, Rimini, Italy, May 27-30, pp.137-138.
- Mantis P, Johnson V and Morandi F. 2008. The Bronchial Tree. In Schwarz T and Johnson V (eds.). *BSAVA Manual of Canine and Feline Thoracic Imaging*. British Small Animal Veterinary Association. pp. 228-241.
- Morais HA. 2009. Logical approach to cough. In Proceedings of the 34th WSAVA Congress, São Paulo, Brazil. [http:// www.ivis.org](http://www.ivis.org). Accessed 9 December 2011.
- Owens JM and Biery DN. 1999. *Radiographic Interpretation for the Small Animal Clinician*. 2nd ed. Missouri: Ralston Purina Company. pp. 89-132.
- Sleeper MM and Buchanan JW. 2001. Vertebral scale system to measure heart size in growing puppies. *J Am Vet Med A* 219 (1): 57-59.
- Spier AW. 2011. The Coughing Dog. In *Proceedings of the 82nd FVMA Annual Conference, Florida, USA*. http://www.fvmace.org/FVMA_83rd_Annual_Conference/Proceedings/The_Coughing_Dog.html. Accessed 11 April 2013.

